



Case Study

AYURVEDIC MANAGEMENT OF FEMALE ANDROGENETIC ALOPECIA (*KHALITYA*)

Varsha. V^{1*}, Palak², Sisir Kumar Mandal³

*¹Junior Resident, Final year, ²Junior Resident, First year, ³Professor, Department of Vikriti Vigyan, Faculty of Ayurveda, Institute of Medical Sciences, Banaras Hindu University, India.

Article info

Article History:

Received: 27-05-2025

Accepted: 22-06-2025

Published: 07-07-2025

KEYWORDS:

Androgenetic alopecia [AGA], Ayurveda, Hair Loss, *Jalauka* therapy, *Khalitya*.

ABSTRACT

Androgenetic Alopecia (AGA), or pattern baldness, is a common form of non-scarring hair loss primarily affecting the scalp, with a higher incidence in males. Genetic, hormonal, and environmental factors contribute to its pathogenesis. AGA significantly impacts psychological well-being. Conventional treatments like minoxidil, finasteride, and corticosteroids offer temporary benefits but are associated with adverse effects and recurrence of symptoms, prompting the need for safer alternatives. **Methods:** A 32-year-old female presented in November 2024 with gradual vertex hair loss and a SALT score of 28%. She was treated for one month with *Jalaukavacharana* (leech therapy), external application of *Shirolepa* (herbal paste), and internal *Rasayana* (rejuvenative) medications. **Result:** By the end of treatment, the patient showed visible improvement in scalp condition and hair density, with the SALT score reducing to 12%. **Discussion:** The classical Ayurvedic approach effectively managed AGA by enhancing blood circulation and follicular nourishment, offering a safe and holistic alternative to modern therapies.

INTRODUCTION

Androgenetic alopecia (AGA) or pattern alopecia, is a common form of non-scarring hairloss of scalp affecting both sexes, although its incidence is generally greater in men than in women.^[1] AGA has immense psychological impact on patients irrespective of age or the stage of baldness.^[2] Conventional treatments like corticosteroids, minoxidil, finasteride, but they have lot of side effects like obesity, hypertension, skin atrophy and these patients complaint of spontaneous remission after stopping the treatment^[3]prompting exploration of alternative therapies. In Ayurveda symptoms of androgenetic alopecia is related to *Khalitya*.^[4] *Khalitya* is considered under *Shiroroga*^[5] by most of the authors of classical ayurvedic texts basis of *sthana* (location of disease) and etiopathogenesis of disease. According to *Acharya Charaka* the combination of *Tejas*, heat in the body, along with *Vata dosha* and other *Doshas* causes damage to the hair follicles on the scalp, leading to hair loss.^[6]

Here, we are presenting a case of *Khalitya*, which was successfully treated on the basis of Ayurvedic management of *Khalitya*.

Patient Information

A 32-year-old married female presented to the outpatient department on 26th November 2023 with complaints of progressive hair fall and scalp itching. The patient reported persistent itching of the scalp for the past three years. She gave a history of white vaginal discharge at the age of 12, following which she began experiencing gradual hair loss. Over time, this progressed to a noticeable bald patch over the frontal hairline, causing significant psychological stress. She had previously undergone treatments from other systems of medicine without satisfactory improvement. A family history of hair loss was noted in her sister. The patient is a known case of hypothyroidism for the past seven years and is on regular medication. She has also undergone hysterectomy, oophorectomy, and appendectomy. There is no history of autoimmune disorders, drug allergies, diabetes, and hypertension. The patient reported routine hair coloring and straightening every six months.

Access this article online

Quick Response Code



<https://doi.org/10.47070/ijapr.v13i6.3755>

Published by Mahadev Publications (Regd.)
publication licensed under a Creative Commons
Attribution-NonCommercial-ShareAlike 4.0
International (CC BY-NC-SA 4.0)

Clinical Findings

On examination, it was observed that hair loss was most severe over the vertex region of the scalp, while the right and posterior areas showed comparatively less thinning. The extent of hair loss was evaluated using the Severity of Alopecia Tool (SALT) scale, a standard method for assessing the percentage of scalp hair loss.^[7] No scarring or other dermatological lesions were noted on the scalp. However, mild scaling was present, suggestive of dandruff. The patient appeared generally healthy on physical examination, with a body mass index (BMI) of 24.7 (weight: 60kg; height: 156cm). Vital signs were within normal limits, with a blood pressure of 124/80 mmHg and a pulse rate of 74 beats per minute. The

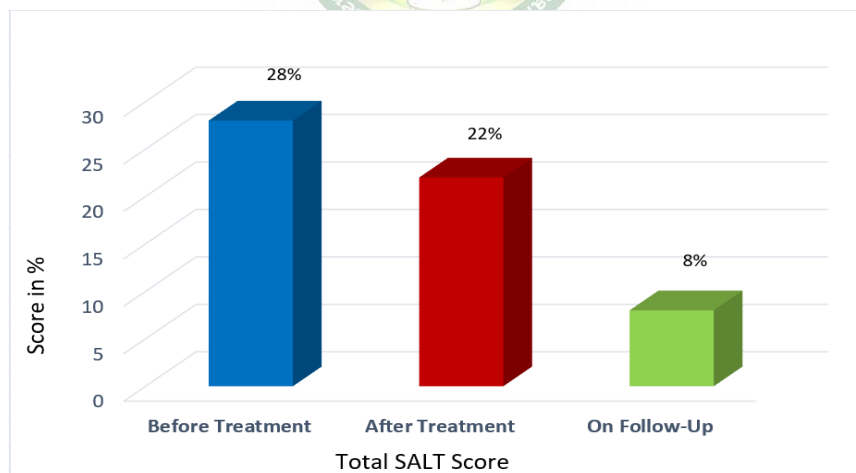
patient had *Vata pradhana pitta prakriti* (physical constitution). No loss of sensation or any discharge was observed over the scalp. Routine hematological, biochemical, and urine investigations were within the limits, Thyroid function tests confirmed known hypothyroidism, for which the patient was already under medication.

Diagnostic Assessments

Based on the observed symptoms progressive hair thinning over the frontal vertex region, positive hair pull test, and a SALT score of 28%, the case was diagnosed as *Khalitya* (Androgenetic Alopecia). Hence, the diagnosis of Androgenetic Alopecia was confirmed, correlating with both Ayurvedic and modern clinical understanding.

Table 1: Observations of Scalp Examination

Site	Scalp
Hair Color	Black
Hair Loss Pattern	Diffuse thinning, predominantly over vertex and frontal region, non-scarring.
Pattern	Symmetrical
Dandruff	Mild, present
Trichoscopy Finding	Hair shaft miniaturization, variation in hair diameter, yellow dots.
Jacquet's Sign	Negative
Hair Pull Test	Positive
SALT Score	28%



Graph 1: Effect of treatment on Total Severity of Alopecia Tool Score

Table 2: Timeline of case and Ayurvedic management

Date and year	Clinical events	Interventions
November 24, 2023	Assessment done and medication started. Hair loss severity was recorded as 28% SALT score.	Planned for <i>Jalauka</i> therapy. <i>Satavarichoorna</i> , <i>Giloyachoorna</i> , <i>Goksura choorna</i> , <i>Amalakichoorna</i> each 2gm <i>Godanti Bhasma</i> - 500mg given after meal twice daily. <i>Rakta gunja beeja choorna</i> + <i>Tankana Bhasma</i> + hibiscus powder for local application with

		coconut oil.
December 13, 2023	Initial improvements observed with a noticeable reduction in scalp itching and mild reduction in hair fall.	First sitting of <i>Jalauka</i> therapy done. Continuation of same medication.
January 04, 2024	Hair fall decreased and sparse regrowth of hair seen on vertex area of scalp.	Second sitting of <i>Jalauka</i> therapy and Continuation of same medication.
February 06, 2024	Hair fall decreased further and regrowth of hair seen on vertex as well as the left, right, and posterior area of scalp.	Third sitting of <i>Jalauka</i> therapy and continuation of same medication.
March 09, 2024	Further hair growth was visible, hair fall had significantly reduced.	Patient came for regular follow-up <i>Kumaryasava</i> - 15ml twice daily was added with above medication.
April 20, 2024	Sustained hair regrowth continued. SALT score improved from 28% to 8%. Patient expressed satisfaction and relief with the outcome.	Patient came for follow-up

FIGURES

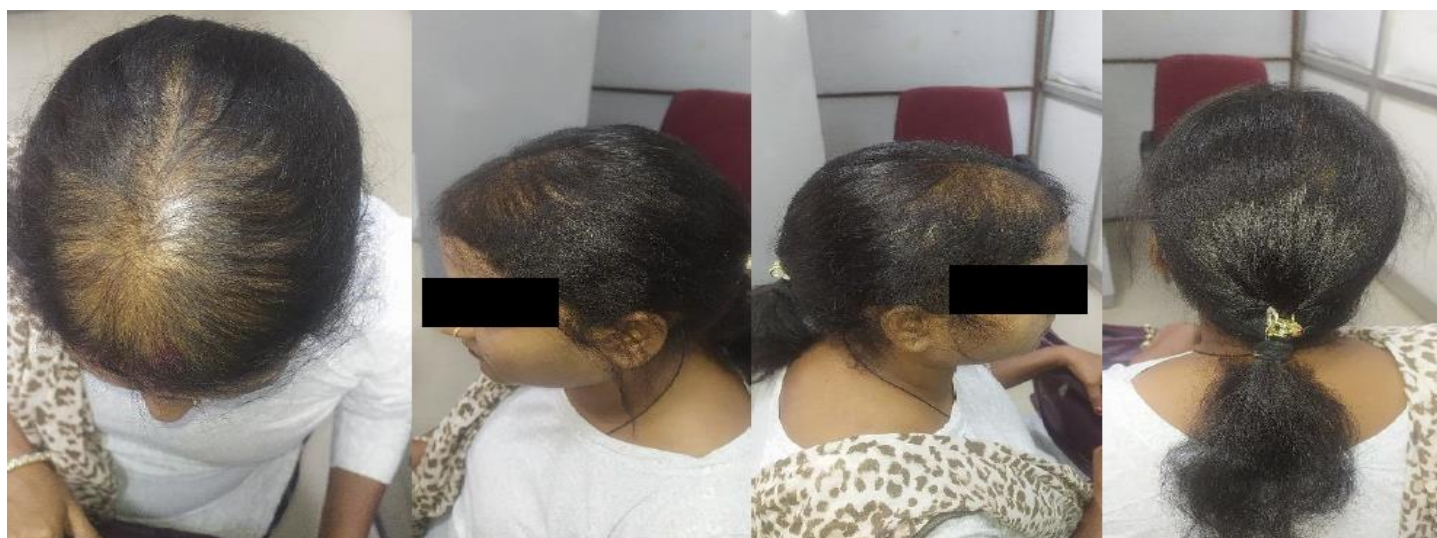

Figure 1: Before treatment on November 24, 2023

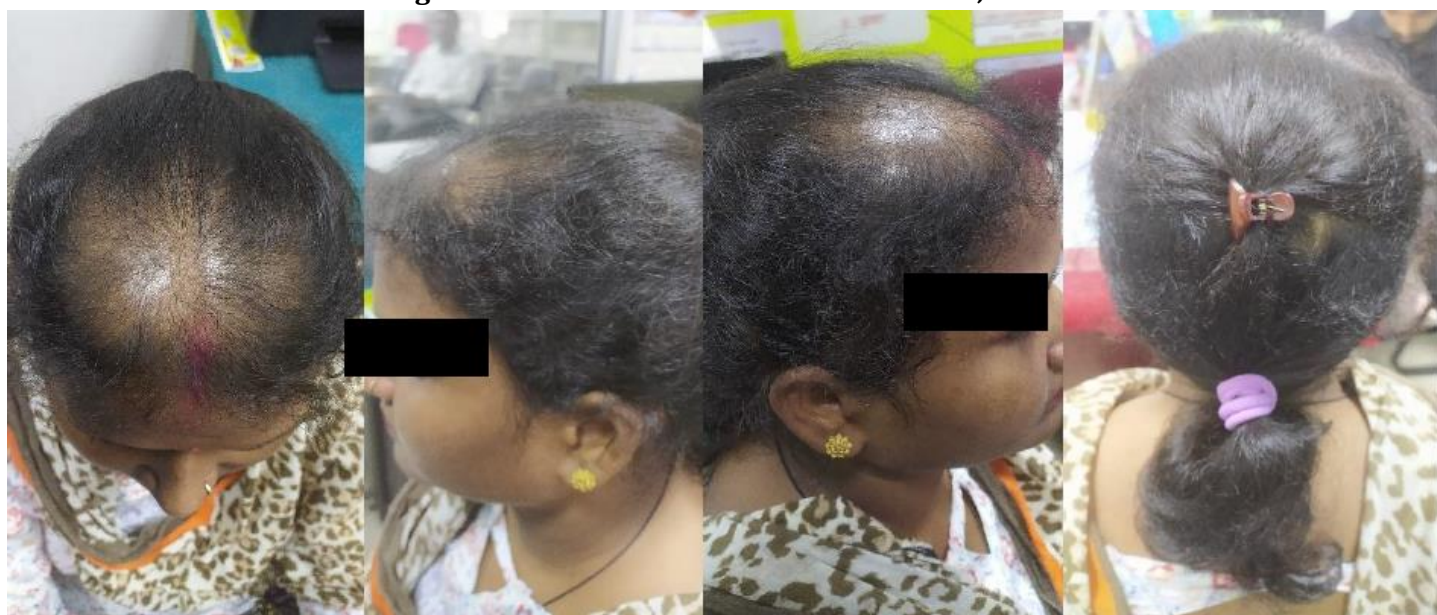

Figure 2: First sitting of *Jalaukavacharana* on December 13, 2023

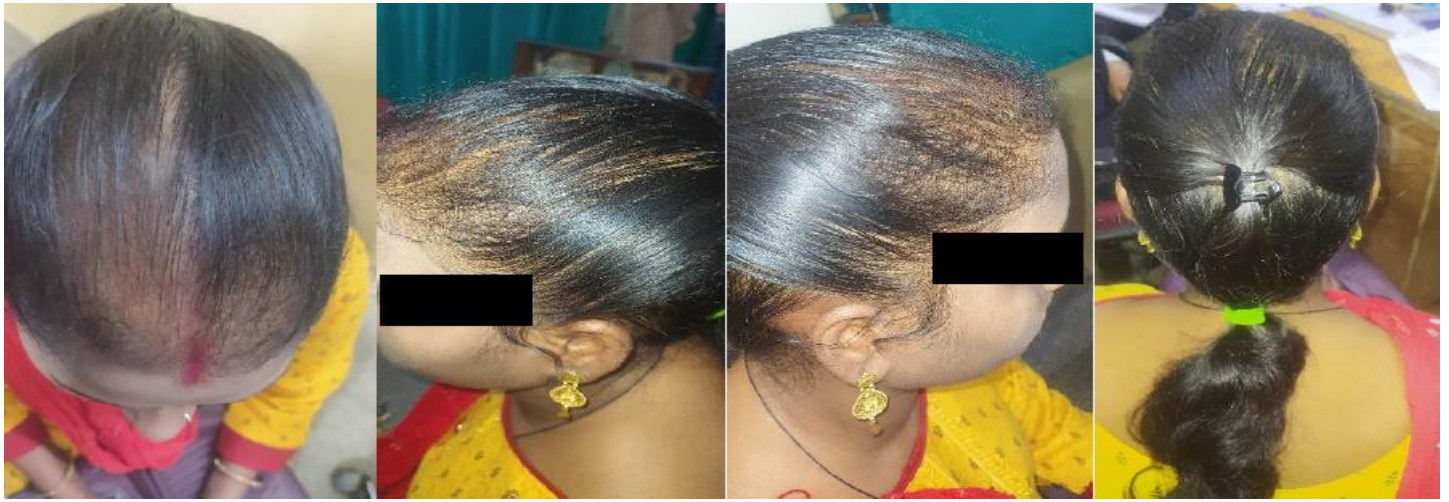

Figure 3: Second sitting of *Jalaukavacharana* on January 04,2024

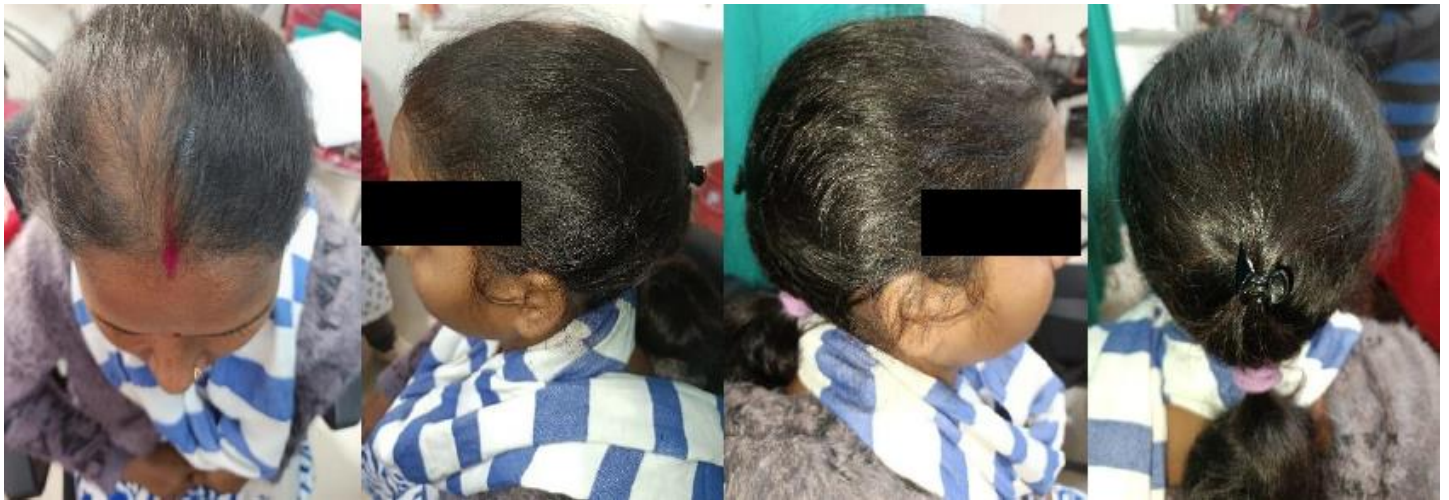

Figure 4: Third sitting of *Jalaukavacharana* on February 06,2024

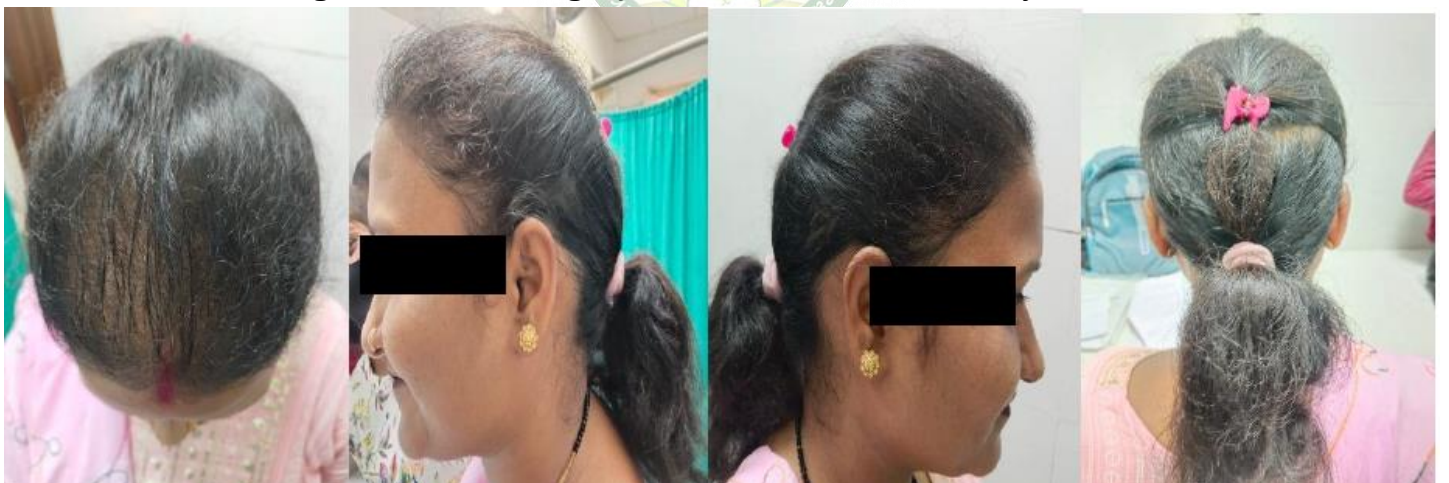

Figure 5: At Follow up

Therapeutic Intervention

Treatment included *Shodhana karma* (purificatory therapy) that is *Jalaukavacharana* (application of leech). As per Ayurvedic literature application of *Jalauka* (leeches) on diseased area is a type of *Raktamokshana* (blood-letting) under *Panchakarma Chikitsa*. *Raktamokshana* is one of the treatment modalities mentioned for *Raktapradoshaja Vikaras*. Leech therapy is one of the simplest techniques that can be used in old or a woman, or an

infant, or a person of an extremely tender constitution.^[8] Blood vitiated by *Pitta* should be removed from the body by using *Jalauka*. Total three sittings of *Jalaukavacharana* (leech therapy) was done along with internal and local medications up to 6 months. Application of *Jalauka* was done as per methodology described by Ayurved text with all aseptic precautions. The composition of oral administration of drug was *Rasayana choorna*, *Satavari*

choorna and *Godanti bhasma*. Details of medications and procedures have been depicted in Table 2.

The patient's condition was checked regularly during follow-up visits to the OPD. In the first few days, there was no change in hair fall, but dandruff had reduced. In the next 14 days, dandruff continued to decrease, but hair fall still didn't improve. After two sitting of *Jalaukavacharana*, hair fall started to reduce, and some new hair growth was seen on the top of the head. This improvement kept going for the next one and a half months. After 5 months, there was a big reduction in hair fall and thick hair regrowth was seen on the top, sides, and back of the scalp [Table 1]. The SALT score showed major improvement, with hair loss reducing from 28% to 8% [Graphs 1]. The hair also looked better in terms of quality, thickness, and fullness, which could be clearly seen [Figures 1–5].

DISCUSSION

This case highlights the successful Ayurvedic management of Androgenetic Alopecia (AGA) using a holistic treatment approach combining *Jalaukavacharana* (leech therapy), internal *Rasayana* medications, and external herbal applications. The strength of this case lies in its integrative strategy that addresses the root causes from an Ayurvedic perspective, emphasizing *Dosha* balance, improved circulation, and tissue rejuvenation. *Jaloukavacharana*, a form of *Raktamokshana*, enhances local blood flow and helps remove vitiated blood, which aligns with the Ayurvedic pathogenesis of *Khalitya* involving vitiated *Pitta* and *Vata* doshas affecting the scalp follicles. *Rasayana Choorna* and *Shatavari Choorna* are classical Ayurvedic formulations recognized for their rejuvenative and adaptogenic properties. *Rasayana churna* owing to its immune-modulatory and rejuvenation properties helps in regeneration of new hair and also in continuous nourishment of hair^[9]. *Shatavari* (*Asparagus racemosus* Wild.), a key ingredient, is widely studied for its phytoestrogenic effects and hormonal regulatory actions, making it beneficial in conditions involving hormonal imbalances such as AGA, especially in women with underlying endocrine disturbances like hypothyroidism^[10]. Together, these formulations support the regeneration of hair follicles by improving cellular nutrition and balancing aggravated doshas, particularly *Vata* and *Pitta*. *Godanti Bhasma*, an Ayurvedic preparation from gypsum, is traditionally used to strengthen bones and support endocrine function. It is rich in bioavailable calcium and has been shown to stabilize metabolic activity, indirectly contributing to hair root strength and hormonal health^[11]. This is particularly relevant in AGA, where hormonal influence on follicular miniaturization is a central factor.

Kumaryasava, a Ayurvedic preparation containing *Aloe vera*, is known to increase digestion, improve liver function, and regulate hormones, which is vital in cases with hypothyroidism, as seen in this patient. Improved *Agni* (digestive fire) enhances the assimilation of nutrients necessary for healthy hair growth^[12]. For local therapy, the use of *Rakta Gunja* (*Abrus precatorius* L.) *Beejachoorna*, *Tankana Bhasma*, and *Hibiscus rosa-sinensis* powder in a base of coconut oil provided direct nourishment to the scalp. These herbs are known for their *Keshya* (hair-promoting) properties. *Rakta Gunja* stimulates circulation and has follicle-stimulating effects, while hibiscus promotes anagen phase activity and conditions the scalp^[13,14]. Coconut oil serves as an excellent carrier, offering antimicrobial and moisturizing benefits that improve overall scalp health and enhance the absorption of active herbal ingredients.

CONCLUSION

This case report highlights the potential of an integrative Ayurvedic approach in effectively managing Androgenetic Alopecia. The combined use of *Jalaukavacharana*, *Rasayana* therapy, and herbal applications not only improved hair density but also addressed the underlying *Doshic* imbalance and hormonal issues. The primary takeaway is that individualized Ayurvedic treatment can offer a safe, cost-effective, and holistic alternative to conventional therapies, with minimal side effects and better patient compliance. Further studies are needed to validate these outcomes on a larger scale.

Declaration of patient consent

Authors certify that they have obtained patient consent form, where the patient has given her consent for reporting the case along with the images and other clinical information in the journal. The patient understands that her name and initials will not be published and due efforts will be made to conceal his/her identity, but anonymity cannot be guaranteed.

Acknowledgement

The authors would like to thank the Department of Vikriti Vigyan, Faculty of Ayurveda, Institute of Medical Sciences, Banaras Hindu University for allowing us to conduct the study. I would like to thank my supervisor for his constant guidance and support towards the completion of this study. I would also like to thank all my co-authors for the support in the preparation of this manuscript.

REFERENCES

1. Sadhan. Blumeyer A, Tosti A, Messenger A, Reygagne P, Del Marmol V, Spuls PI, et al. Evidence-based (S3) guideline for the treatment of androgenetic alopecia in women and in men. J Dtsch Dermatol Ges. 2011; 9(Suppl 6): S1–57. doi: 10.1111/j.1610-0379.2011.07802.x.

2. Kaliyadan F, Nambiar A, Vijayaraghavan S. Androgenetic alopecia: An update. Indian J Dermatol Venereol Leprol. 2013; 79: 613-25. doi: 10.4103/0378-6323.116730.
3. Olsen E, Clinical tools for assessing hair loss, in Olsen E(ed): disorders of hair growth : Diagnosis and treatment. New York, McGraw -Hill, 2003, p.g.75-85.
4. Sushruta. Sushruta Samhita Nidana Sthana 13/34 with the Nibandhasangraha commentary by Dalhanacharya. Chaukhamba Surbharati Prakashan, Varanasi: 2023. p-565-567.
5. Vagbhata. Ashtanga Hridaya Samhita Uttara Sthana 23/24-25 with English translation by Srikantamurthy K.R. 4th ed. Krishnadas Academy, Varanasi: 2000. p-222
6. Sharma RK, Bhagwan Dash. Caraka Samhita (Eng. Translation) Vol. II Chikitsasthana 26/132 Varanasi; Chaukhamba Sanskrit Series Office; p.g-510
7. Olsen EA, Hordinsky MK, Price VH, Roberts JL, Shapiro J, Canfield D, et al. Alopecia areata investigational assessment guidelines – Part II. National alopecia areata foundation. J Am Acad Dermatol 2004; 51: 440-7.
8. Sushruta. Sushruta Samhita Sutra Sthana 13/3 with English translation by Srikanta murthy K.R. 4th ed. Krishnadas Academy, Varanasi: 2000. P.g -78
9. Hardik S, Surendra B, Biswajyoti P. Standardization of Rasayana churna – A classical ayurvedic formulation. Int J Res Pharm Sci 2013; 4: 283-9.
10. Sharma PV. Dravyaguna Vijnana, Vol. II, Chaukhambha Bharati Academy, Varanasi.
11. Panda AK, Jadav HR. "Pharmacognostical and Analytical Study of Godanti Bhasma." AYU, 2012; 33(4): 561-565.
12. Puri HS. Rasayana: Ayurvedic Herbs for Longevity and Rejuvenation, Taylor & Francis, 2003.
13. Rathi V, Rathi JC, Trivedi PC. "Hibiscus rosa-sinensis: A Review on its Ethnobotany, Phytochemical and Pharmacological Profile." Journal of Pharmacognosy and Phytochemistry, 2013; 2(2): 108-113.
14. Dahanukar SA, Kulkarni RA, Rege NN. "Pharmacology of Medicinal Plants and Natural Products." Indian Journal of Pharmacology, 2000; 32: S81-S118.

Cite this article as:

Varsha. V, Palak, Sisir Kumar Mandal. Ayurvedic Management of Female Androgenetic Alopecia (Khalitya). International Journal of Ayurveda and Pharma Research. 2025;13(6):75-80.

<https://doi.org/10.47070/ijapr.v13i6.3755>

Source of support: Nil, Conflict of interest: None Declared

***Address for correspondence**

Dr. Varsha. V

Junior Resident, Final year,
Department of Vikriti Vigyan,
Faculty of Ayurveda,
Institute of Medical Sciences,
Banaras Hindu University
Email: varshavkarthika22@gmail.com

Disclaimer: IJAPR is solely owned by Mahadev Publications - dedicated to publish quality research, while every effort has been taken to verify the accuracy of the content published in our Journal. IJAPR cannot accept any responsibility or liability for the articles content which are published. The views expressed in articles by our contributing authors are not necessarily those of IJAPR editor or editorial board members.